

## **Metal Artifact Reduction in Flat-Detector CT Acquisitions of Stent-Assisted Coiled Intracranial Aneurysms**

**Poster No.:** C-1951  
**Congress:** ECR 2013  
**Type:** Scientific Exhibit  
**Authors:** P. van de Haar, D. Ruijters, J. Timmer; Best/NL  
**Keywords:** Artifacts, Aneurysms, Stents, Embolisation, Computer Applications-3D, CT-High Resolution, CT-Angiography, Cone beam CT, Neuroradiology brain, Interventional vascular, Head and neck  
**DOI:** 10.1594/ecr2013/C-1951

Any information contained in this pdf file is automatically generated from digital material submitted to EPOS by third parties in the form of scientific presentations. References to any names, marks, products, or services of third parties or hypertext links to third-party sites or information are provided solely as a convenience to you and do not in any way constitute or imply ECR's endorsement, sponsorship or recommendation of the third party, information, product or service. ECR is not responsible for the content of these pages and does not make any representations regarding the content or accuracy of material in this file.

As per copyright regulations, any unauthorised use of the material or parts thereof as well as commercial reproduction or multiple distribution by any traditional or electronically based reproduction/publication method is strictly prohibited.

You agree to defend, indemnify, and hold ECR harmless from and against any and all claims, damages, costs, and expenses, including attorneys' fees, arising from or related to your use of these pages.

Please note: Links to movies, ppt slideshows and any other multimedia files are not available in the pdf version of presentations.

[www.myESR.org](http://www.myESR.org)

## Purpose

In recent years the imaging capabilities of flat detector C-arm X-ray systems have been improved. Flat Detector Computed Tomography (FDCT) has become increasingly popular within minimally invasive endovascular interventions [1,2]. Very recently it has become feasible to visualize stents that possess very low radiopacity. The FDCT images offer the possibility to inspect the stent deployment with respect to the vessel lumen and intravascular plaques [3,4]. However, tomographic images of stents that are placed adjacent to aneurysms filled with coils are severely distorted by streaking artifacts caused by the metal coils. In this article, results are reported on reducing these artifacts in a second pass reconstruction.

## Methods and Materials

### VasoCT - High resolution FDCT of intracranial stents

For the purpose of imaging intracranial stents and their surrounding vasculature a dedicated acquisition protocol and reconstruction settings have been developed (VasoCT; Philips Healthcare, Best, the Netherlands) [3]. The high resolution protocol consists of 620 projection images acquired over a rotational trajectory of 200°, while the imaged detector area is set to a diameter of 22 cm and using a pixel size of 0.154 mm. The X-ray tube voltage is set to 80 kV, the focal spot to 0.4 mm, while no additional copper filter is used. This protocol enables very high spatial resolution 3D reconstructions.

The high resolution protocol can be combined with the injection of iodine contrast medium (either an intravenous injection, or an on-site intra-cranial injection of diluted contrast), in order to inspect the interface between stent and vessel lumen. In this manner it is possible to assess whether the stent has been properly deployed.

Patel et al. [4] have documented the resulting benefits in spatial resolution, as can be seen by comparing [Fig. 1](#) on page 3 (regular soft-tissue FDCT) and [Fig. 2](#) on page 5 (VasoCT reconstruction).

### Metal artifact reduction

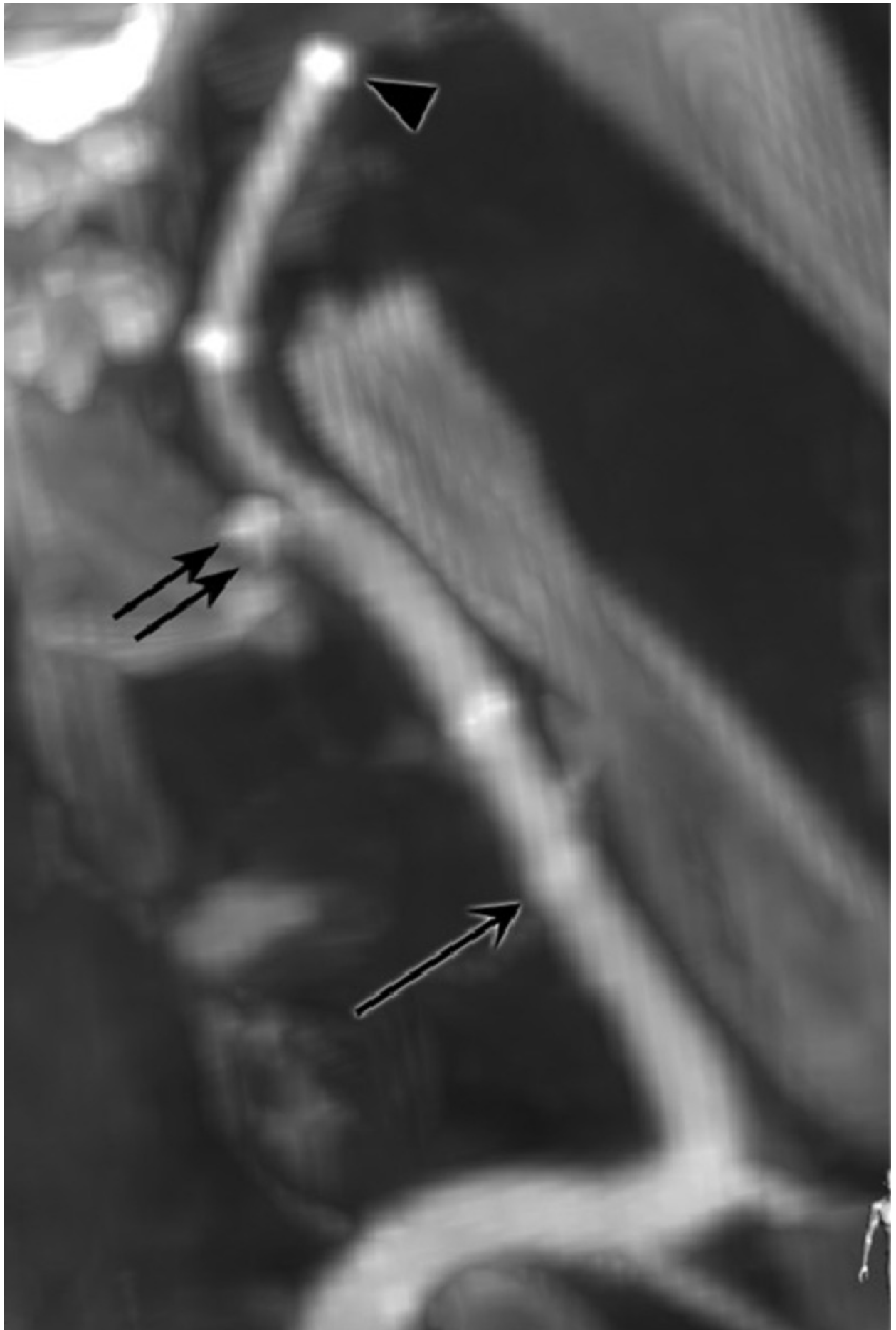
In the first step of the Metal Artifact Reduction (MAR) algorithm [5] a regular filtered back-projection reconstruction is produced [6]. From this reconstruction the volumetric regions that display high X-ray absorption (such as metal) are identified. These regions are then forward projected [7] on the original X-ray images (see [Fig. 3](#) on page 7 and [Fig. 4](#) on page 7), in order to process the high-absorption areas in the images. These

processed images are then used to create an improved reconstruction in a second pass. The entire process of two passes is performed within about 138 seconds.

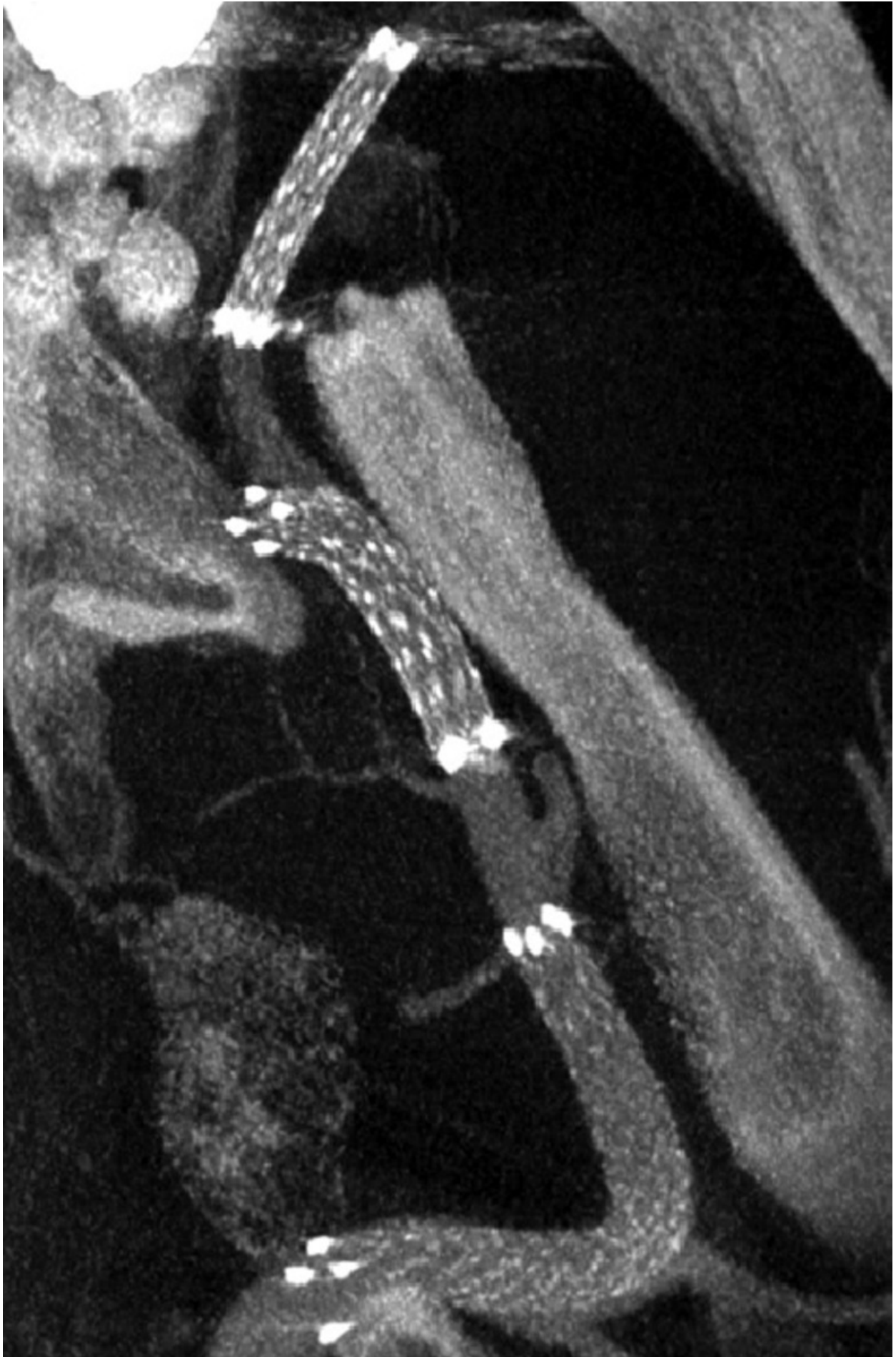## **Materials**

FDCT volumetric reconstructions with endovascularly treated aneurysms were obtained, while diluted iodine contrast (10% contrast medium and 90% normal saline) was selectively injected in the feeding artery to show the vessel lumen. The aneurysms had been filled with coils and stents had been placed to close the neck of the aneurysms. A second pass reconstruction algorithm was used to correct for the streaking artifacts that originate from the coiled volume.

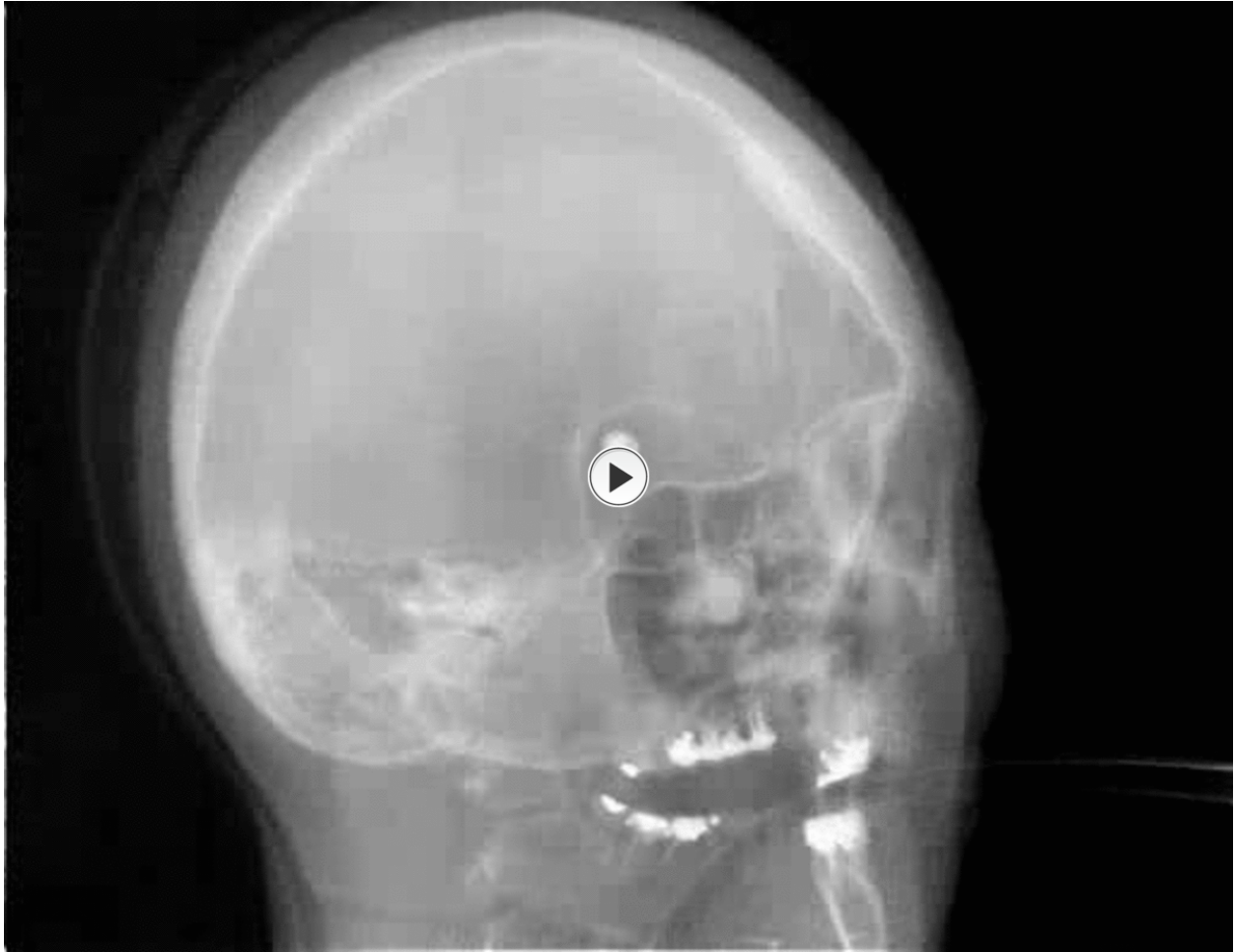## **Images for this section:**




**Fig. 1:** FDCT reconstruction of stents placed in a swine model obtained with a standard soft-tissue protocol. Adapted from Patel et al. [3].



**Fig. 2:** High-resolution VasoCT reconstruction of stents placed in a swine model. Adapted from Patel et al. [3].



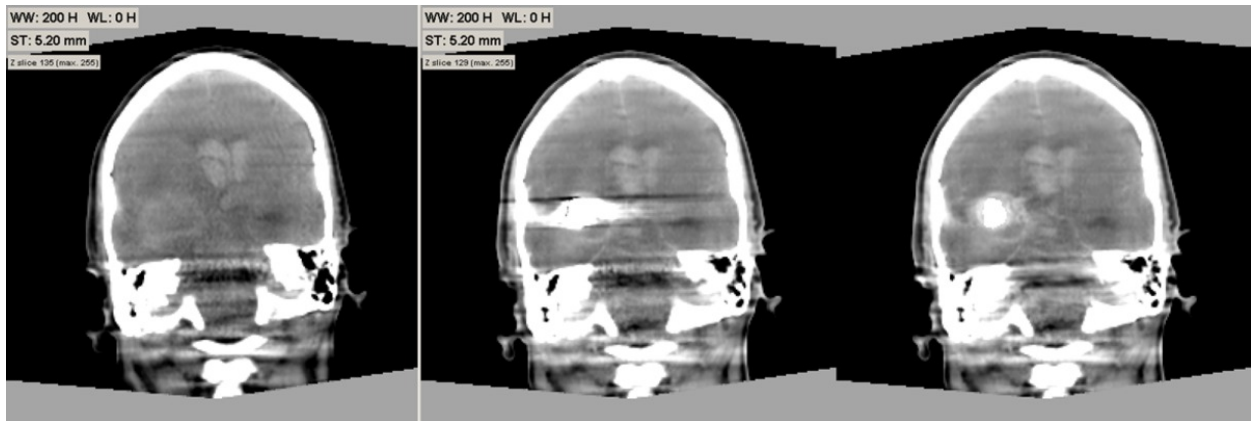
**Fig. 3:** Rotational acquisition showing high X-ray absorption in the coiled aneurysm and teeth fillings.



**Fig. 4:** High X-ray absorption areas segmented in the rotational acquisition.



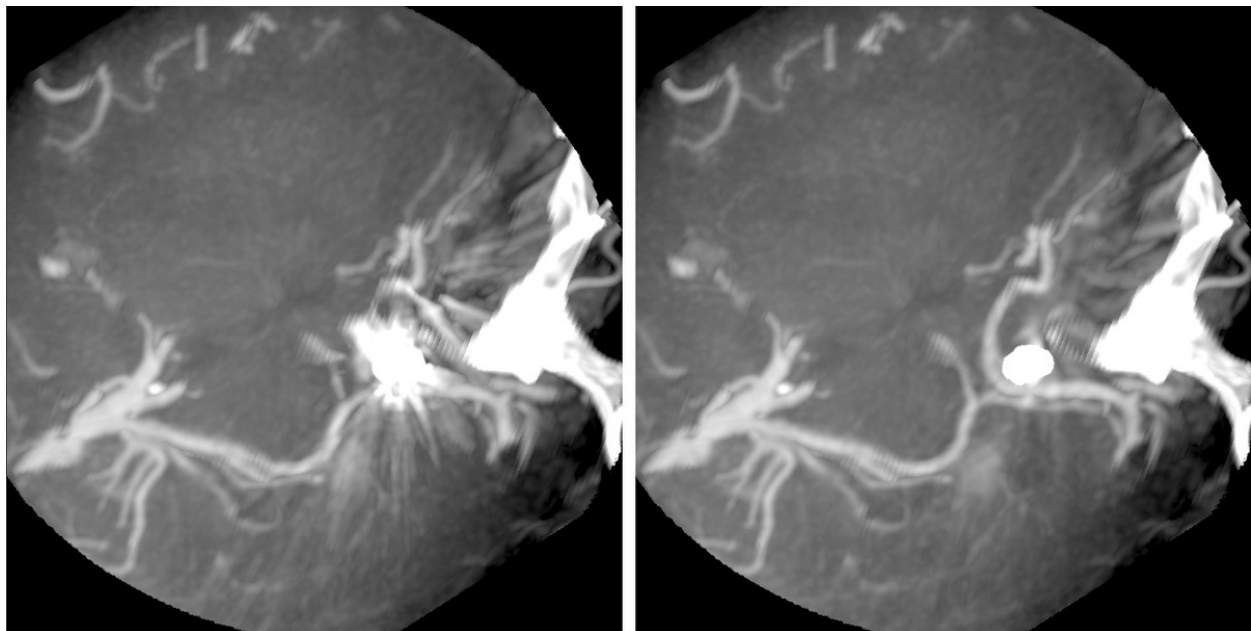
## Results



**Fig. 5:** Left: pre-interventional FDCT reconstruction. Middle: post-coiling reconstruction without MAR. Right: post-coiling reconstruction with MAR applied.

**References:** interventional X-Ray Innovation, Philips Healthcare - Best/NL

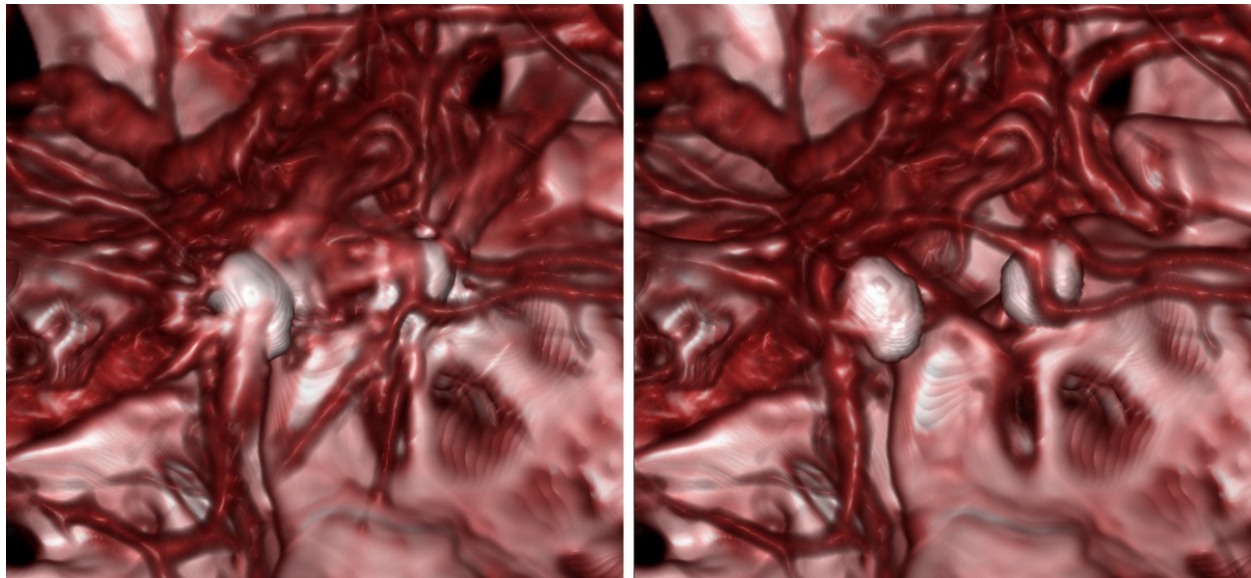
Fig. 5 on page shows a pre-interventional FDCT and a post coiling FDCT without and with MAR applied, in order to illustrate the MAR technique. The streaking artifacts have been reduced significantly in the reconstruction with MAR applied. Soft-tissue structures that are obstructed by the streaking artifacts originating from the coils in the aneurysm sac are clearly visible in the reconstruction with MAR.



**Fig. 6:** Axial slab in a contrast enhanced FDCT reconstruction. Left: without MAR. Right: with MAR applied.

**References:** interventional X-Ray Innovation, Philips Healthcare - Best/NL

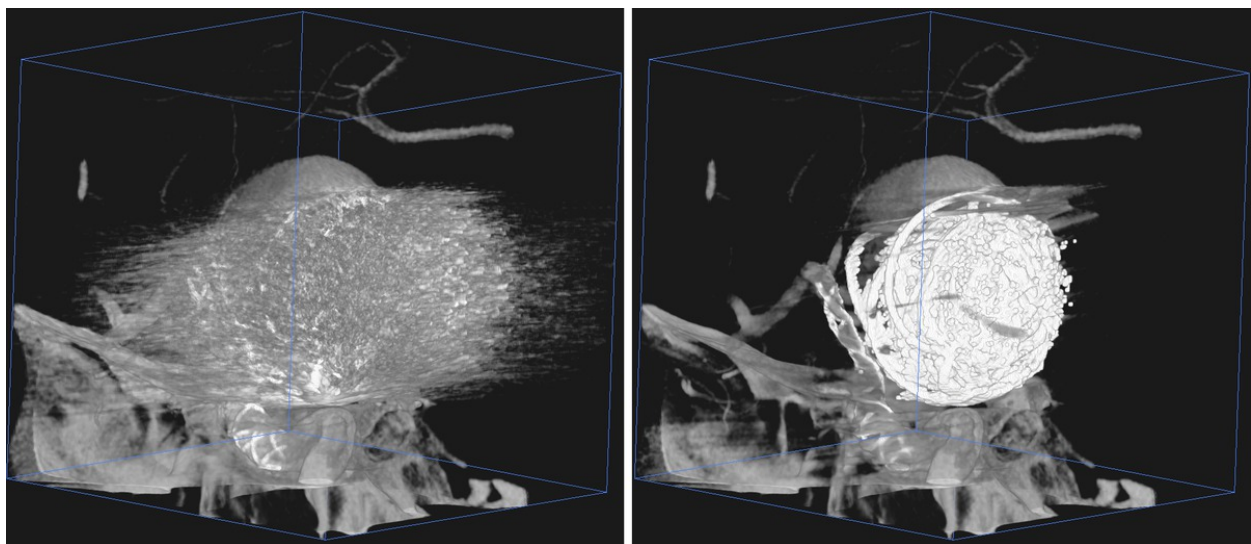
In Fig. 6 on page            a reconstruction of a coiled aneurysm is shown, while the vessels have been filled with diluted contrast medium. The second pass reconstruction (right) shows clearly the vasculature obstructed by the artifacts in the first pass reconstruction (left).



**Fig. 7:** Zoomed 3D rendering of a contrast enhanced FDCT reconstruction. Left: without MAR. Right: with MAR applied.

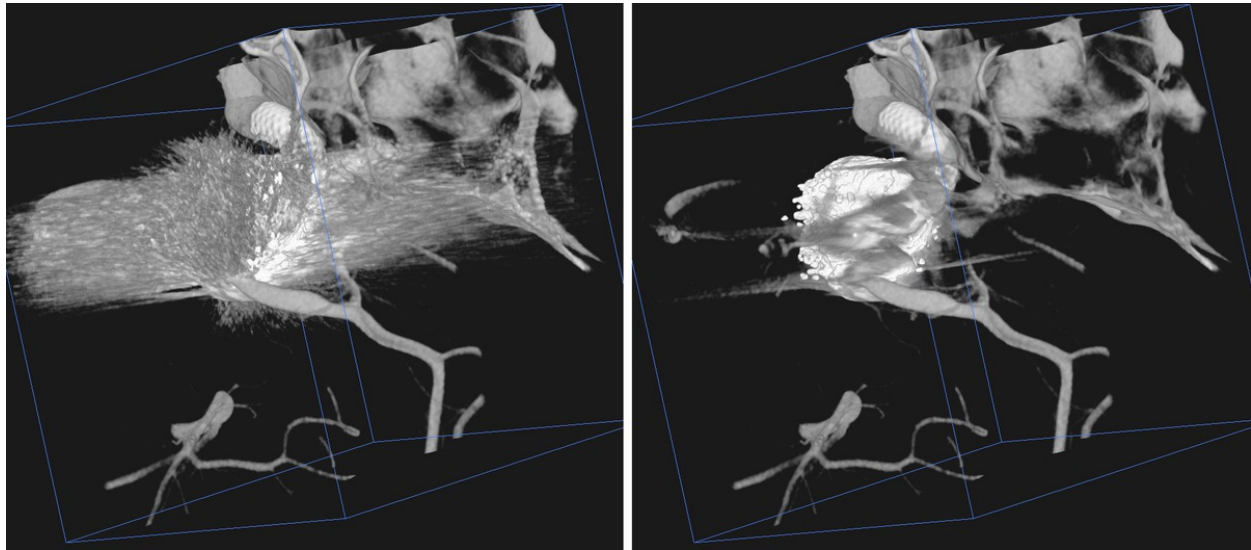
**References:** interventional X-Ray Innovation, Philips Healthcare - Best/NL

Fig. 7 on page            shows a 3D visualization of the reconstruction in Fig. 6 on page            . The streaking artifacts that origin from the coils can form false vessel lumen in the 3D representation (left), whereas this effect is not present in the MAR corrected image (right).



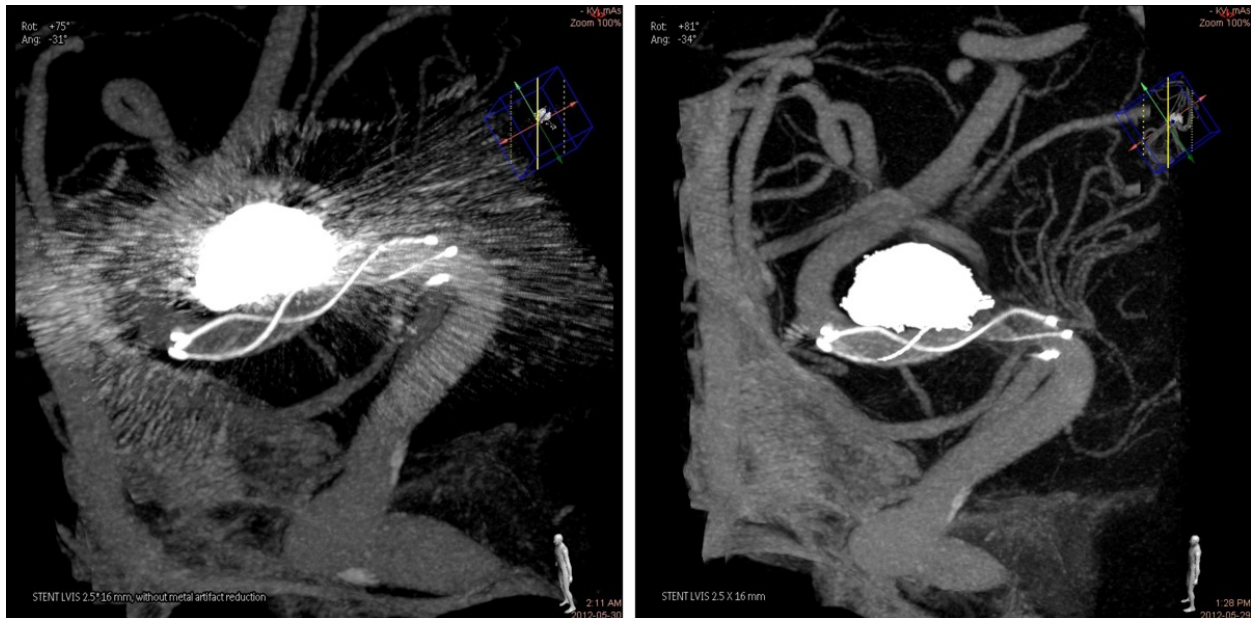
**Fig. 8:** Contrast enhanced FDCT reconstruction of a stent-assisted coiled large aneurysm. Left: without MAR. Right: with MAR applied.

**References:** interventional X-Ray Innovation, Philips Healthcare - Best/NL



**Fig. 9:** Contrast enhanced FDCT reconstruction of a stent-assisted coiled aneurysm. Left: without MAR. Right: with MAR applied.

**References:** interventional X-Ray Innovation, Philips Healthcare - Best/NL



**Fig. 10:** Contrast enhanced FDCT reconstruction of a stent-assisted coiled aneurysm. Left: without MAR. Right: with MAR applied.

**References:** Courtesy: Prof. J. Moret, Neuri Hôpital Beaujon, Paris.

Fig. 8 on page , Fig. 9 on page , and Fig. 10 on page display volumetric visualizations of stent assisted coiled aneurysms. The left images show the

reconstructions without MAR applied, and the right images are the result of the MAR algorithm. Though not all stent struts affected by the metal artifacts can be reconstructed in the second pass, the visibility of the stents has improved considerably.

## Conclusion

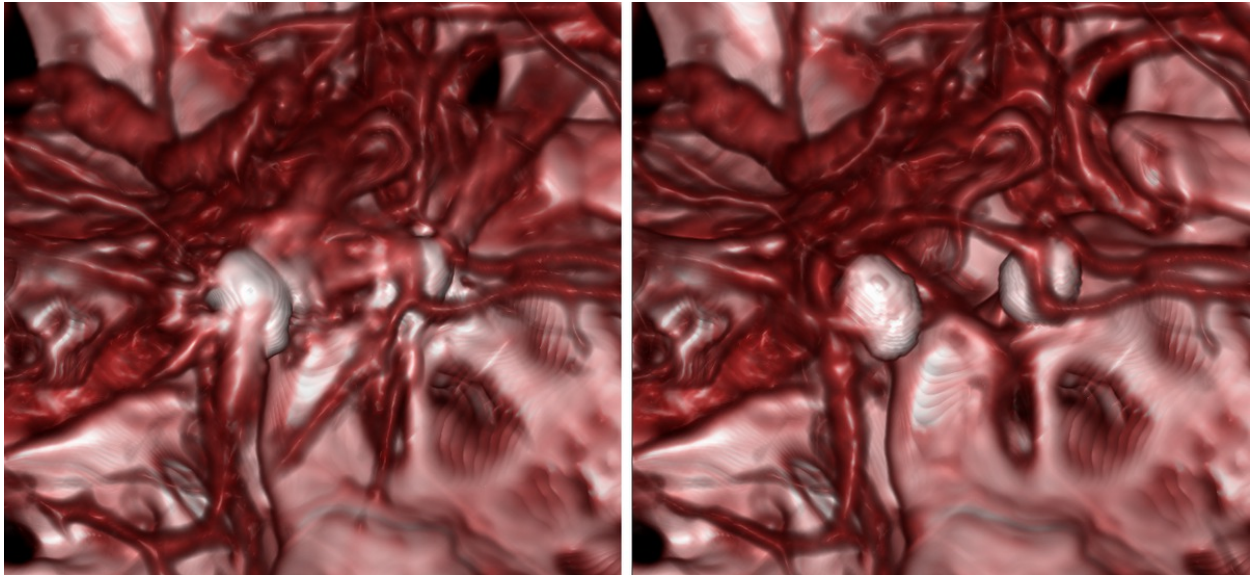
The MAR procedure significantly reduces the presence of metal streaking artifacts caused by coils placed in aneurysms. This allows the investigation of tissue and anatomical structures adjacent to the coiled volume. In case of stent/coils combinations this is especially valuable, since the streaks tend to obscure the intracranial stent. Observers in a recent study [8] gave significantly higher scores to MAR corrected FDCT images regarding the visibility of the arteries and stents adjacent to coiled aneurysms.

Especially when diluted iodine contrast medium is administered to perform a VasoCT reconstruction, enabling to examine the vascular morphology, streaking artifacts severely disturb the evaluation of the aneurysm neck. On top of that false vessel bifurcations and branches may be introduced by the streaking artifacts. The MAR procedure largely resolves these disturbing phenomena. It removes the false bifurcations and branches, and enables the clear visualization of the aneurysm neck.

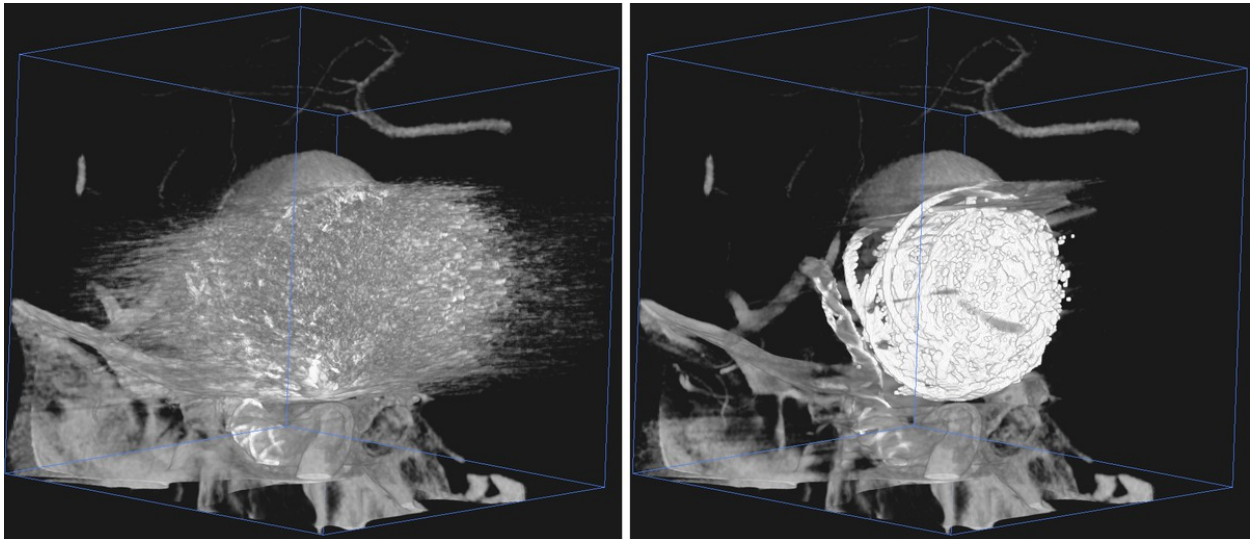
The improved second pass reconstructions significantly benefit the clinical interpretation of the tomographic images. Especially, the assessment of the stent deployment with respect to the vessel lumen is enhanced significantly for stents that are placed close to coiled aneurysms.

MAR cannot fully remove all metal artifacts. Typically, some streak-artifacts remain. The intensity of the remaining streaks depends on the complexity of nearby anatomy (like bone structures), size of metal object etc. Soft-tissue imaging of very low-contrasts will still suffer from artifacts, but the artifact level has been significantly reduced. Overall the diagnostic value of the MAR reconstructed images has been greatly enhanced, due to the considerable reduction of the artifacts.

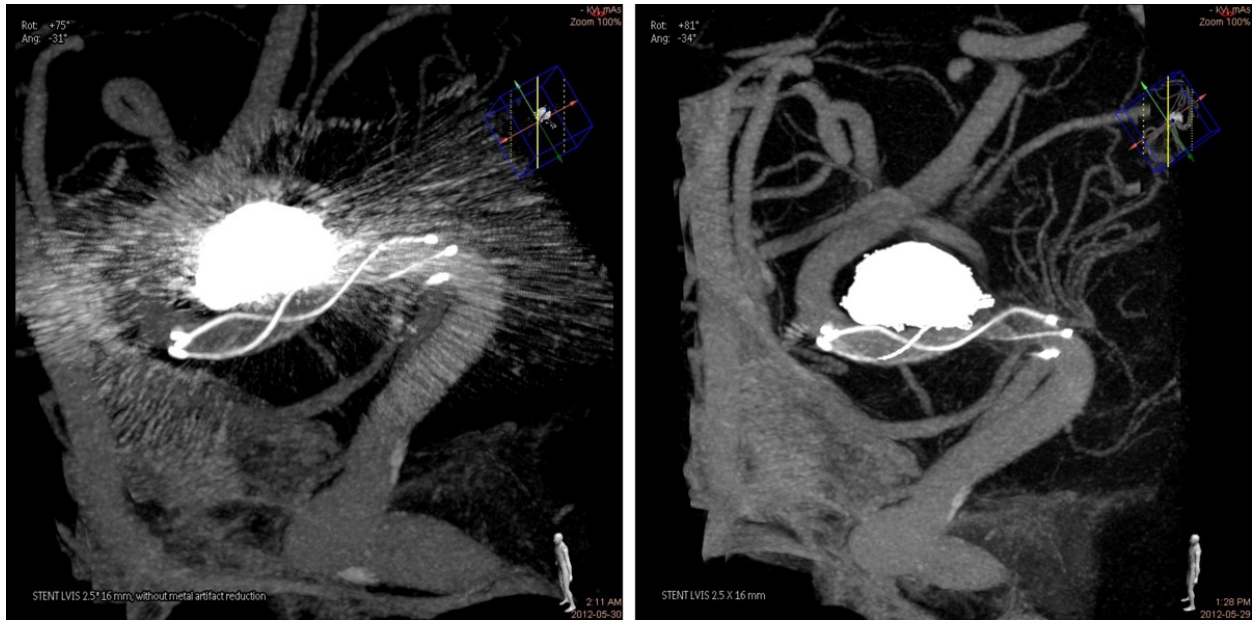
**Images for this section:**



**Fig. 7:** Zoomed 3D rendering of a contrast enhanced FDCT reconstruction. Left: without MAR. Right: with MAR applied.



**Fig. 8:** Contrast enhanced FDCT reconstruction of a stent-assisted coiled large aneurysm. Left: without MAR. Right: with MAR applied.



**Fig. 10:** Contrast enhanced FDCT reconstruction of a stent-assisted coiled aneurysm. Left: without MAR. Right: with MAR applied.

## References

1. Söderman M, Babic D, Holmin S, Andersson T (2008): Brain imaging with a flat detector C-arm, Technique and clinical interest of XperCT. *Neuroradiol* 50:863-868
2. Kamran M, Nagaraja S, Byrne JV (2010): C-arm flat detector computed tomography: the technique and its applications in interventional neuro-radiology. *Neuroradiol* 52:319-27
3. Snoeren RM, Söderman M, Kroon JN, Roijers RB, de With PHN, Babic D (2012): High-resolution 3D X-ray imaging of intracranial nitinol stents. *Neuroradiology* 54(2):155-162
4. Patel NV, Gounis MJ, Wakhloo AK, Noordhoek N, Blijd J, Babic D, Takhtani D, Lee S-K, Norbash A (2011): Contrast-Enhanced Angiographic Cone-beam CT of Cerebrovascular Stents: Experimental Optimization and Clinical Application. *AJNR* 32:137-144
5. Prell D, Kyriakou Y, Struffert T, Dorfler A, Kalender WA (2010): Metal Artifact Reduction for Clipping and Coiling in Interventional C-Arm CT. *AJNR Am J Neuroradiol* 31:634-39
6. Feldkamp LA, Davis LC, Kress JW (1984): Practical cone-beam algorithm. *J Opt Soc Am A* 1:612-19
7. Ruijters D, ter Haar Romeny BM, Suetens P (2008): GPU-Accelerated Digitally Reconstructed Radiographs. *Proc. IASTED BioMed*:431-435
8. van der Bom IMJ, Hou SV, Puri AS, Spilberg G, Ruijters D, van de Haar P, Carelsen B, Gounis MJ, Wakhloo AK (2013): Reduction of coil mass artifacts in high resolution flat-detector cone-beam computed tomography of cerebral stent-assisted coiling, *AJNR Am J Neuroradiol*, in press.

## Personal Information

Peter van de Haar, Daniel Ruijters, Jan Timmer

interventional X-Ray,

Philips Healthcare,

Veenpluis 4-6,

5680DA Best, the Netherlands

mailto: [danny.ruijters@philips.com](mailto:danny.ruijters@philips.com)