

## Frame-less C-arm Needle Guidance

### Abstract

Daniel Ruijters<sup>1,3</sup>, Drazenko Babic<sup>1</sup>, Robert Homan<sup>1</sup>, Peter Mielekamp<sup>1</sup>, Bart M. ter Haar Romeny<sup>2</sup>, Paul Suetens<sup>3</sup>

<sup>1</sup> X-Ray Predevelopment, Philips Healthcare, Best, the Netherlands

<sup>2</sup> Biomedical Image Analysis, Technische Universiteit Eindhoven, the Netherlands

<sup>3</sup> Medical Image Computing, ESAT/Radiologie, Katholieke Universiteit Leuven, Belgium

### Abstract

We present a method that integrates soft-tissue information in X-ray fluoroscopy guided needle insertion, without the use of a stereotactic frame.

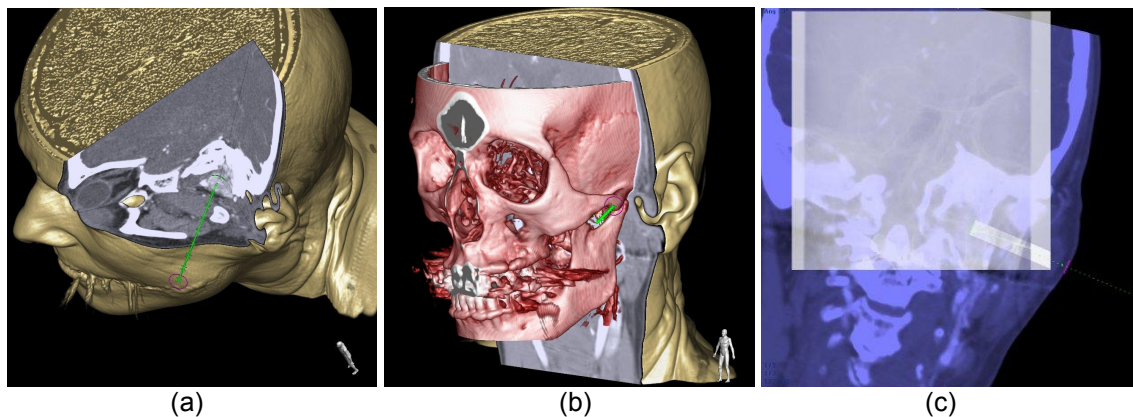
Before the puncture is performed, the optimal needle paths are planned on a pre-operative CT dataset, see figure (a). At the beginning of the intervention a 3D soft-tissue XperCT dataset is acquired with the C-arm X-ray system, and the pre-operative CT dataset is registered to the peri-operative XperCT, which also registers the CT and C-arm coordinate systems, see figure (b).

The C-arm viewing incidence is steered to be tangent to the planned path: the entry view. Since this view is tangent to the needle trajectory, the path is foreshortened to a single point. When the needle is positioned at the entry position and its orientation is tangent to the fluoroscopy image, it can be inserted.

The C-arm viewing incidence is then steered to be perpendicular to the planned path: the progression view, see figure (c). In this orientation, the needle can be navigated along the planned trajectory.

The live fluoroscopy image is overlaid with the planned needle trajectory and fused with an oblique slice of the soft-tissue data, perpendicular to the viewing incidence and passing through the target point. The overlay image is real-time updated for any change in viewing incidence (L-arm, rotation, angulation), field of view, and source-image distance. The needle path is compensated for parallax distortion.

The entry view and progression view steps are repeated for all planned puncture paths. The views can be selected at table side. Optionally, new paths can be planned during the intervention. After the insertion, a new XperCT can be acquired to verify the needle position with regard to the soft-tissue structures and anatomical landmarks.



(a) Needle path, with respect to the soft-tissue, bones, vessel and skin.

(b) The XperCT volume (red) is peri-interventionally registered to the CT volume (yellow).

(c) Progression view. Real-time X-ray fluoroscopy is overlaid on the oblique slab in the CT data, through which the planned trajectory passes.

## Related work

- Racadio J.M., Babic D., Homan R., Rampton J.W., Patel M.N., Racadio J.M., Johnson N.D.: Live 3D Guidance in the Interventional Radiology Suite, American Journal of Roentgenology, pp. 189:W357-W364, 2007.
- Söderman M., Babic D., Homan R., Andersson T.: 3D roadmap in neuroangiography: technique and clinical interest, Neuroradiology 47(10), pp. 735-740, 2005.
- Giansante Abud D., Mounayer C., Benndorf G., Piotin M., Spelle L., Moret J.: Intratumoral Injection of Cyanoacrylate Glue in Head and Neck Paragangliomas, American Journal of Neuroradiology 25, pp. 1457-1462, October 2004.
- Maes F., Collignon A., Vandermeulen D., Marchal G., and Suetens P.: Multimodality Image Registration by Maximization of Mutual Information, IEEE Trans. Medical Imaging 16(2), pp. 187-198, 1997.
- Ruijters D., Spelle L., Moret J., Babic D., Homan R., Mielekamp P., ter Haar Romeny B.M., Suetens P.: XperGuide: C-arm Needle Guidance, In Proc. European Congress of Radiology - ECR 2008; Vienna, Austria, C-591, European Radiology 18, Supp.1, February 2008, p. 459